

# RhinoCycle Tests



**Interacoustics<sup>®</sup>**

leading diagnostic solutions

## Measuring

RhinoCycle is a complete 24-hour recording and investigation system for examination of the nasal cycle. The module performs long-term measurement of the inspiration (and expiration) flow through each nostril.

The pressure fluctuations during nasal inspiration are transmitted to connected pressure transducers at the data-logger with the help of a nasal cannula fitted on both nasal sides at the bottom of the nasal vestibule. The measured data are recorded by an inbuilt memory. The time period of the measurement is freely selectable, but we recommend a 24-hours recording time.

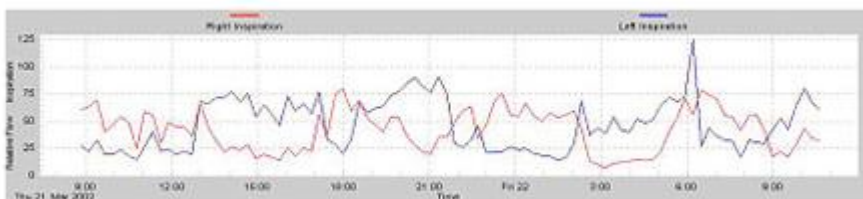
The used pressure transducers are calibrated at a linear pressure-flow relationship and therefore the pressure can be used as a direct measure of nasal flow during inspiration. Since the pressure-flow relation is linear the nasal flow is exactly quantifiable.

Below you will find links to examples of curves showing different nasal cycles recorded with the RhinoCycle module, both normal and also pathological nasal cycles.


### Typical nasal cycle, short/Typical nasal cycle, long

The illustrations below show two examples of a typical nasal cycle with reciprocal and simultaneous change of the cyclic phases. The duration and alteration of the cyclic phases will vary from person to person.

The duration of the cyclic phases is short:




The duration of the cyclic phases is long:



### Patient with an In-concert Nasal Cycle

This example shows an in-concert type of nasal cycle, meaning that the left and right nasal sides are both in the same cyclic phase. The result of this state is that the airflow is high during day and low during the night in both nasal sides at the same time.



### Patient with Septum Deviation

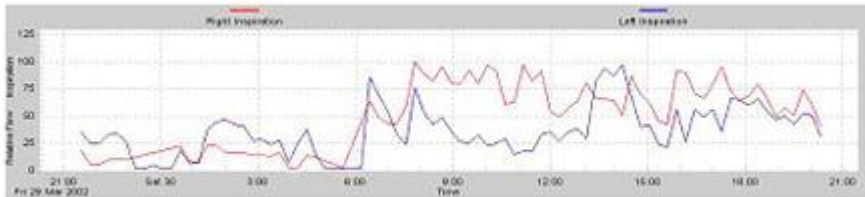
This example shows a person with a deviation of the septum in the right nostril. The duration of the

working phases is clearly shorter for the narrow, right side than for the left nasal side.



### Patient with a Nocturnal Nasal Obstruction

This illustration below represents the measurement of a patient who had a nasal obstruction especially during the night, where a clearly decreased flow is observed.



(The data is shown by courtesy of C. Lang, S. Grützmacher, B. Mlynski and G. Mlynski, University of Greifswald, Germany.)